

Fickes Holistic Care Corp

Changes in Thermal Images

824 Hahaione St.,

Honolulu, Hawaii 96821 USA

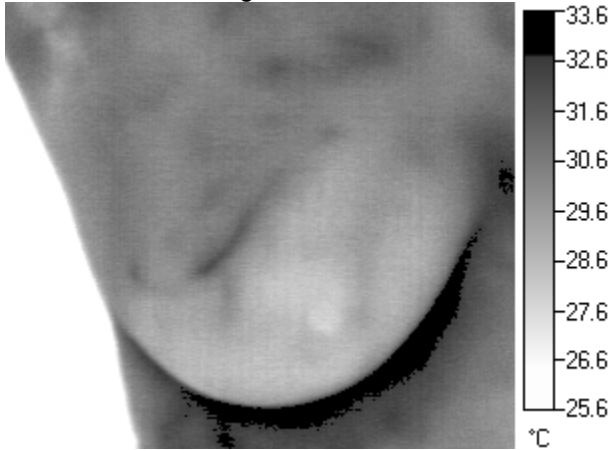
Phone: 808 395-6800 Fax: 808 396-0919

Reported By: Dr. Linda Fickes, D.C., C.C.N.,
Board Certified Medical
Thermographer

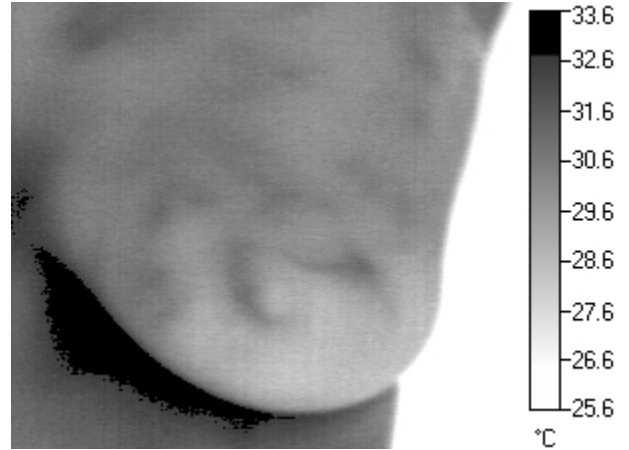
Subject 1.

Example of diminished estrogen dominance and improvement in breast health with nutritional care. Female, age 53.

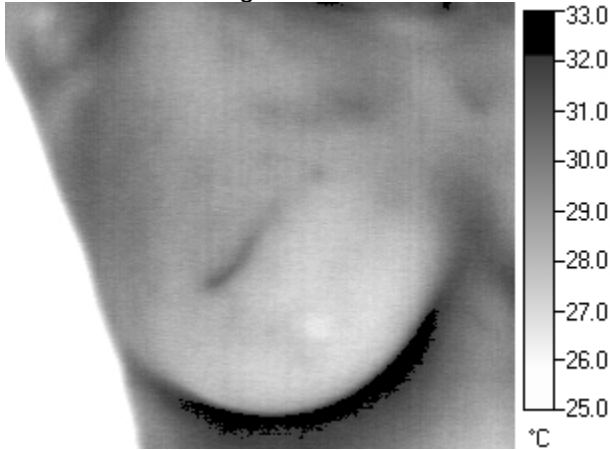
Ant. Right Breast 3/10/09



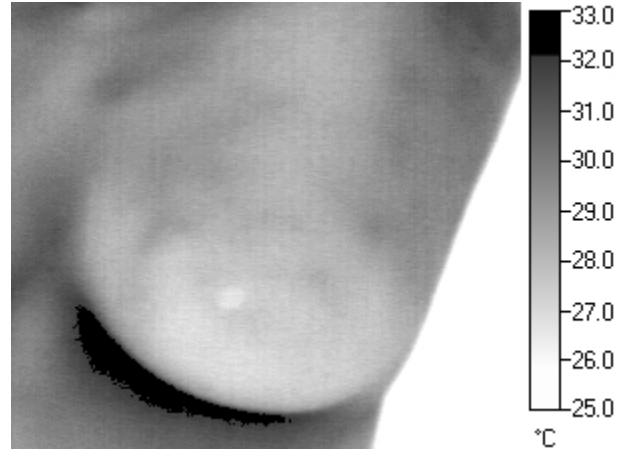
Ant. Left Breast 3/10/09



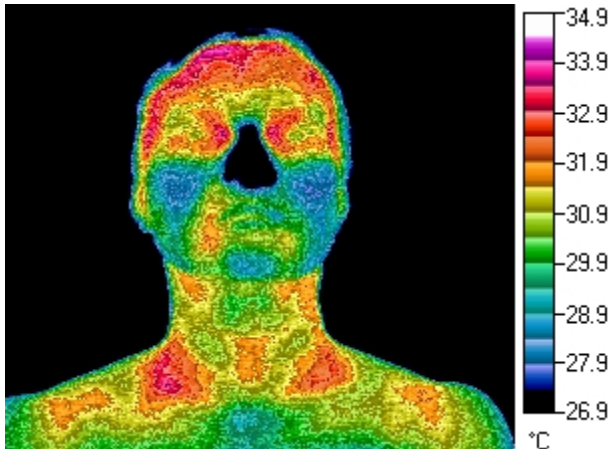
Ant. Right Breast 4/14/10



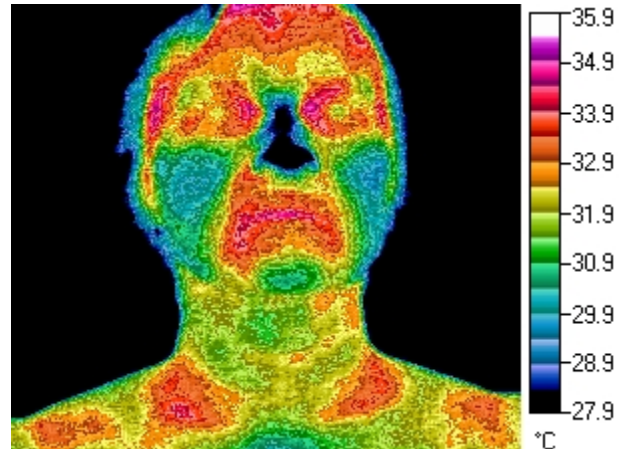
Ant. Left Breast 4/14/10



Ant. Cranial Facial 4/14/10

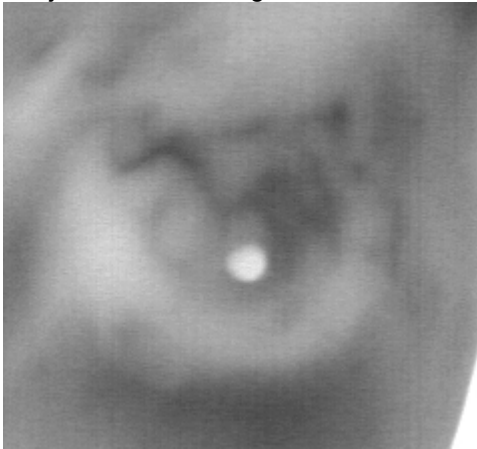

Ant. Cranial Facial 3/09

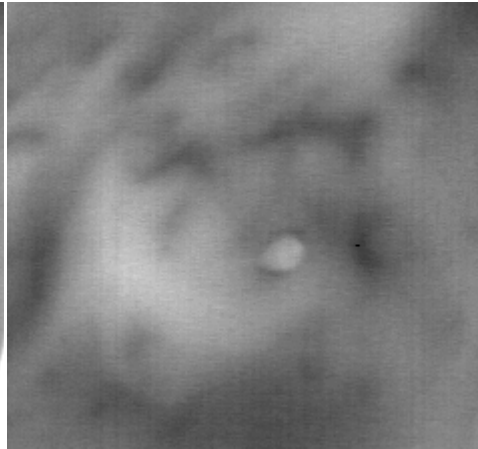


Now more thyroid heat and activity and less radiation caused mouth heat from outgassing dental materials from cell use.

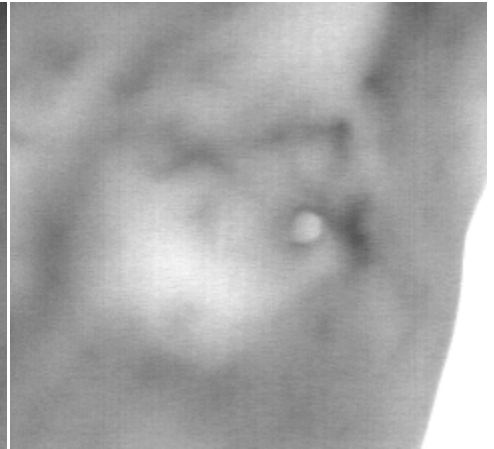
Subject 2, Female, Age 48



7/07 Breast cancer

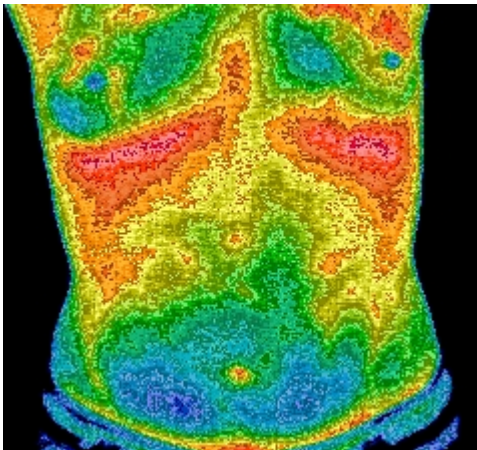


2/09 Post surgery

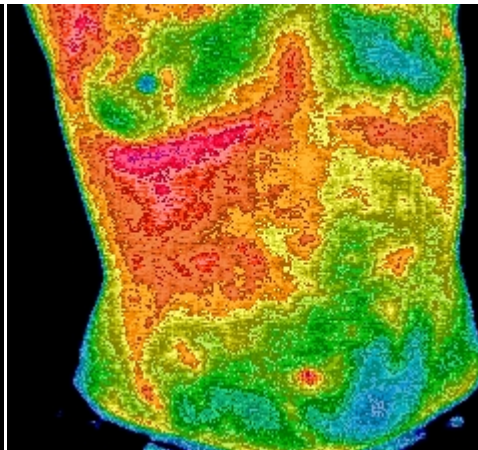


3/10 Continued healing, no chemo or radiation, natural therapies

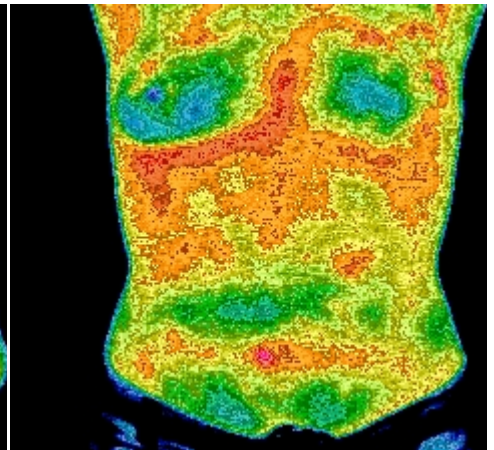
Same woman as above with the left breast cancer.



7/07 Left Breast Cancer
Excessive heat in liver and pancreas

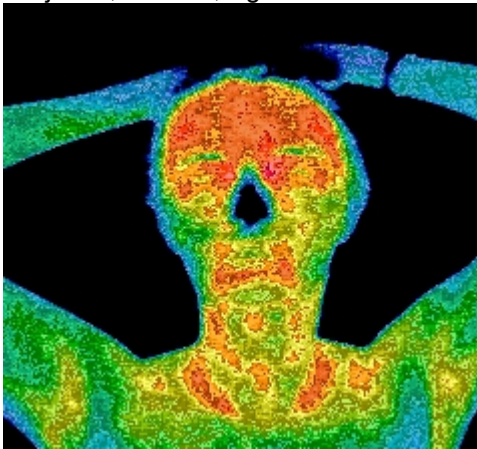


2/09 Post surgery
Pancreas improved, severe liver heat/detoxing

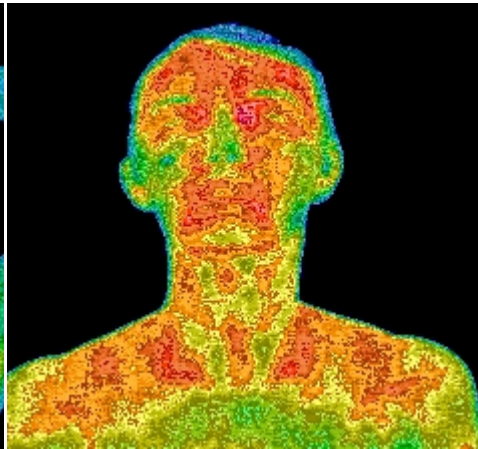


3/10 Continuing natural healing
Pancreas better, liver improving.

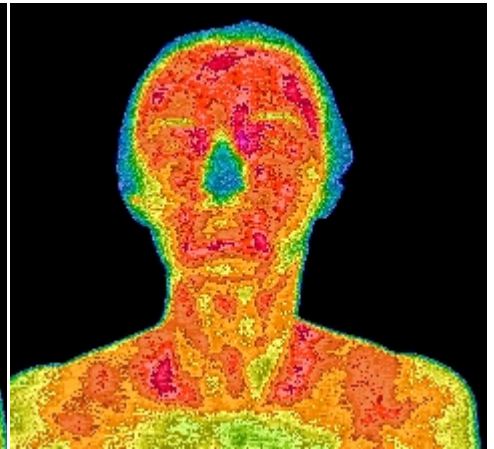
Subject 3, Female, Age 63



4/07 Mild radiation exposure

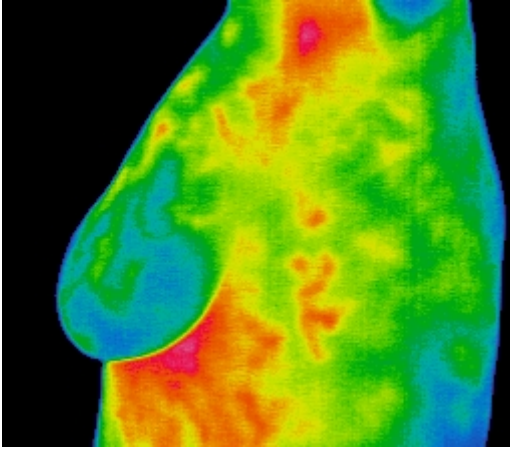


9/08 Wifi installed, no radiation protection

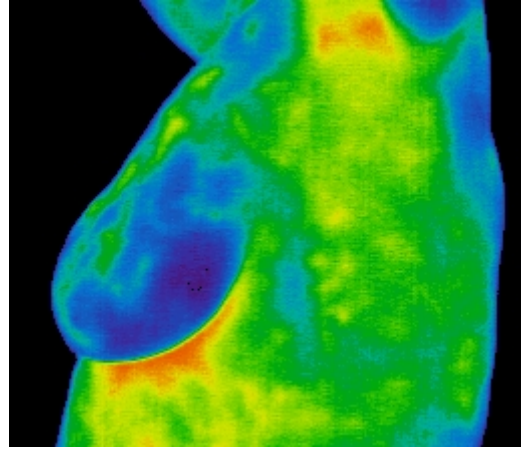


3/10 More Wifi exposure, cell phones and cordless phones, computers unprotected. Severe outgassing of dental materials and autonomic nervous system stress.

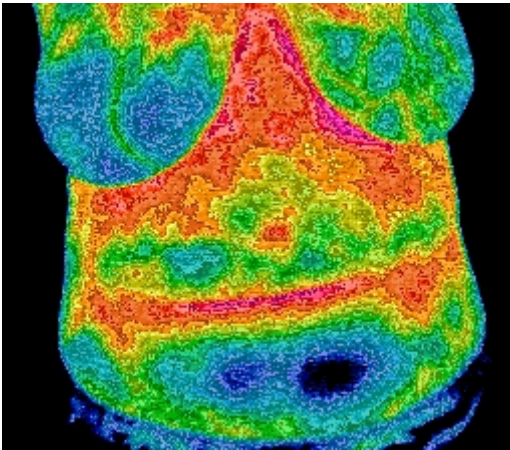
Subject 4, Female, Age 45



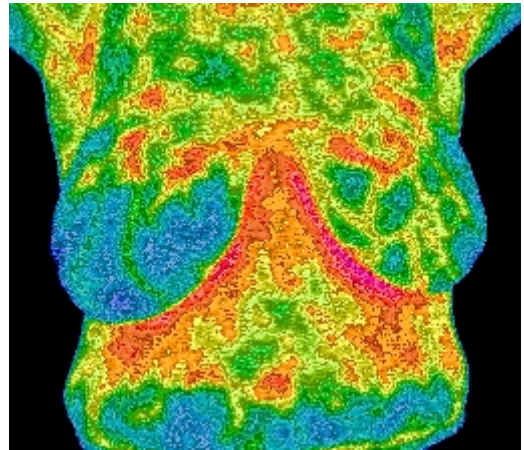
11/09 Severe lymphatic congestion and pancreas heat.




5/10 Significant improvement.



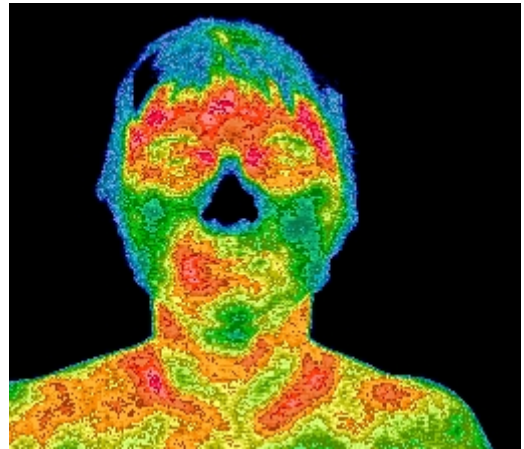
11/09 Same woman as above, severe stomach, liver and pancreas heat.



5/10 Same woman, improved liver, stomach and pancreas heat/inflammation, but more needed.

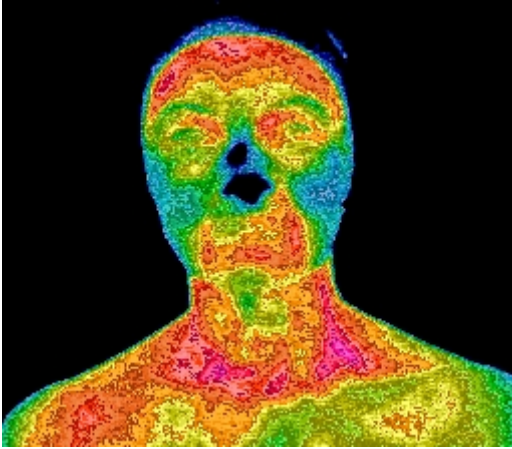


11/09 Same woman, radiation causes toxic dental materials to outgas into sinuses and lymph.

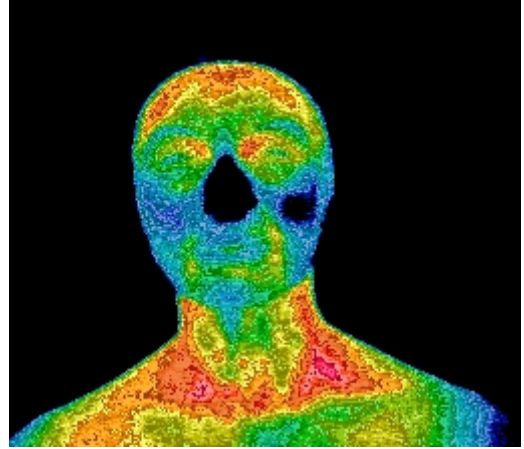


5/10 Same woman using radiation protection. Now only a dental infection is visible in left mouth.

Subject 5, Female, Age 65

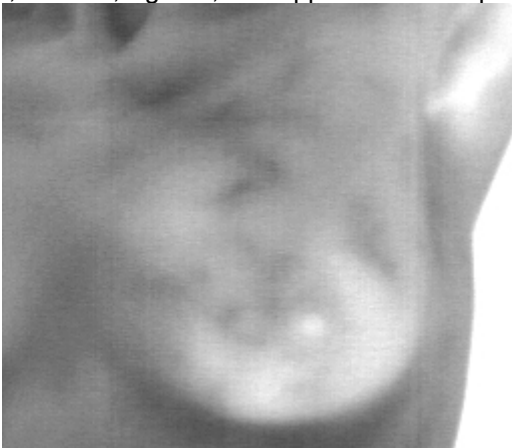

After talking on an unprotected cell phone. Outgassing dental materials.

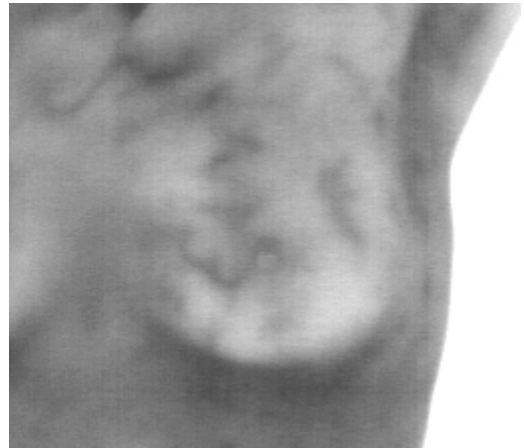

After talking on a GIA Wellness protected cell phone. Normal, optimal mouth heat.

Subject 6, Female, Age 59, Left upper breast lump

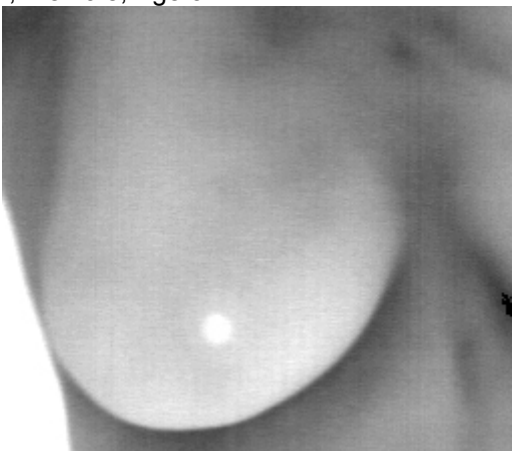


5/07 Mild breast heat changes near lump, moderate risk. No nutritional attention.



4/10 Severe heat changes near lump and areola, severe risk for breast cancer.

Subject 7, Female, Age 52



Normal and optimal breast images.

